

MINERVA

CHIRURGICA

VOL. 66 · SUPPL. 1 · N. 3 · GIUGNO 2011

**SHORT REVIEW ON FACE REJUVENATION PROCEDURES:
FOCUS ON PREOPERATIVE ANTISEPTIC AND
ANESTHETIC DELIVERY BY JETPEEL™-3
(A HIGH PRESSURE OXYGEN DELIVERY DEVICE)**

T. IANNITTI, S. CAPONE, B. PALMIERI



EDIZIONI · MINERVA · MEDICA

MINERVA CHIRURGICA

RIVISTA BIMESTRALE DI CHIRURGIA PRATICA
FONDATA NEL 1946 DA TOMASO OLIARO

COMITATO EDITORIALE

G. Azzena - P. Banna - M. E. Basile - P. Biglioli - L. Corbellini - C. Cordiano - M. Dei Poli
V. Di Carlo - G. Di Matteo - G. Favia - G. Gasparri - S. M. Giulini - E. Lezoche - G. Maggi
V. Memeo - M. Montorsi - F. Morino - M. Morino - G. Motta - A. Mussa - M. Nano
A. E. Paletto - A. Peracchia - G. Pezzuoli - A. Pinna - A. Robecchi - G. Romeo - A. Ruffo
M. Salizzoni - M. L. Santangelo - E. Santoro - C. Staudacher - G. Viola - P. Zannini

REDATTORI

M. Camandona - G. Campanelli - F. Gabrielli - R. Maruotti - G. Olivero - G. Palazzini
M. Roseano - E. Ruffini - M. Sacchi - M. Toppino

DIRETTORE RESPONSABILE

A. Oliaro



This journal is **PEER REVIEWED** and is indexed by *Excerpta Medica/EMBASE, Index Medicus/MEDLINE, MDS, Science Citation Index Expanded/SciSearch*

La Rivista è on-line nel sito web: [www: minervamedica.it](http://www.minervamedica.it)

Direzione, redazione, ufficio grafico, ufficio pubblicità, fotocomposizione, amministrazione - Edizioni Minerva Medica - Corso Bramante 83-85 - 10126 Torino
Tel. 011 67.82.82 - Fax 011 67.45.02 - E-Mail: minervamedica@minervamedica.it - Web Site: minervamedica.it

Stampa - Edizioni Minerva Medica - Tipografia di Saluzzo - Corso IV Novembre 29-31 - 12037 Saluzzo (CN) - Tel. 0175 249405 - Fax 0175 249407

Abbonamento annuo:

Italia - Individuale: Cartaceo € 110,00, Cartaceo+Online € 115,00; **Istituzionale:** Cartaceo € 145,00, Online (Small € 250,00, Medium € 285,00, Large € 330,00, Extra Large € 345,00), Cartaceo+Online (Small € 260,00, Medium € 300,00, Large € 345,00, Extra Large € 360,00); il fascicolo € 30,00.

Unione Europea - Individuale: Cartaceo € 190,00, Cartaceo+Online € 200,00; **Istituzionale:** Cartaceo € 245,00, Online (Small € 250,00, Medium € 285,00, Large € 330,00, Extra Large € 345,00), Cartaceo+Online (Small € 260,00, Medium € 300,00, Large € 345,00, Extra Large € 360,00); il fascicolo € 45,00.

Paesi extraeuropei - Individuale: Cartaceo € 210,00, Cartaceo+Online € 220,00; **Istituzionale:** Cartaceo € 270,00, Online (Small € 275,00, Medium € 310,00, Large € 365,00, Extra Large € 380,00), Cartaceo+Online (Small € 285,00, Medium € 325,00, Large € 380,00, Extra Large € 395,00); il fascicolo € 50,00.

Gli abbonati possono utilizzare le seguenti forme di pagamento: a) assegno bancario; b) bonifico bancario a: Edizioni Minerva Medica, INTESA SANPAOLO Agenzia n. 18 Torino. IBAN: IT45 K030 6909 2191 0000 0002 917 c) conto corrente postale 00279109 intestato a Edizioni Minerva Medica, Corso Bramante 83-85, 10126 Torino; d) carte di credito Diners Club International, Master Card, VISA, American Express

I cambi di indirizzo di spedizione, e-mail o di qualsiasi altro dato di abbonamento vanno segnalati tempestivamente inviando i nuovi e vecchi dati per posta, fax, e-mail o direttamente sul sito www.minervamedica.it alla sezione "I tuoi abbonamenti - Contatta ufficio abbonamenti".

I reclami per i fascicoli mancanti devono pervenire entro 6 mesi dalla data di pubblicazione del fascicolo.

I prezzi dei fascicoli e delle annate arretrati sono disponibili su richiesta.

© Edizioni Minerva Medica - Torino 2011

Tutti i diritti sono riservati. Nessuna parte di questa pubblicazione può essere riprodotta, trasmessa e memorizzata in qualsiasi forma e con qualsiasi mezzo. Pubblicazione bimestrale. Autorizzazione del Tribunale di Torino n. 275 del 30-6-1948. Iscrizione nel registro nazionale della stampa di cui alla legge 5-8-1981 n. 416 art. 11 con il numero 00 148 vol. 2 foglio 377 in data 18-8-1982. Pubblicazione periodica Bimestrale - Poste Italiane S.p.A. - Sped. in a.p. - D. L. 353/2003 (conv. in L. 27/02/2004 N° 46) art. 1, comma 1, DCB/CN

Associata a



La Rivista aderisce al Codice di Autodisciplina degli Editori Medico Scientifici, associati a FARMAMEDIA e può essere oggetto di pianificazione pubblicitaria

Associata a

A.N.E.S.S.

Associazione Nazionale Editoria Specializzata

Short review on face rejuvenation procedures: focus on preoperative antiseptic and anesthetic delivery by JetPeel™-3 (a high pressure oxygen delivery device)

T. IANNITTI ^{1,2}, S. CAPONE ², B. PALMIERI ²

Aim. Nowadays there is great attention in trying to slow and reverse the facial aging process. Esthetic medicine has been primarily based on the surgical approach for many years, but now, in order to solve the problem of aging skin, there is an increasing interest into non-invasive, possibly painless, procedures that can guarantee the patient a quick recovery. In this perspective the use of chemical peeling and dermabrasion, to achieve skin rejuvenation, is growing worldwide. These techniques are also relevant to treat skin pigmentation irregularities and to remove keratoses, lentigines, acne and other skin related conditions. One of the most interesting, safe and painless devices, useful for the effective antiaging face treatment, is JetPeel™-3. The aim of this study was to assess the device efficacy starting from a short review on face rejuvenation procedures.

Methods. The basic action mechanism of this medical device is a constant high pressure air flux delivery, including oxygen, mixed with different chemical compounds such as peeling molecules, antioxidants, vitamins and hyaluronic acid, which are mechanically forced across the skin surface. Here we report a new approach in the clinical use of

Conflicts of interest.—The authors certify that there is no conflict of interest with any financial organization regarding the material discussed in the manuscript.

All the authors contributed equally to this work.

Funding.—This article was not supported by grants.

Received on March 14, 2011.

Accepted for publication on May 31, 2011.

Corresponding author: T. Iannitti, Glasgow Caledonian University, Cowcaddens Road, Charles Oakley Laboratories, G40BA, Glasgow, UK. E-mail: tommaso.iannitti@gmail.com

¹Department of Biological and Biomedical Sciences

Glasgow Caledonian University, Glasgow, UK

²Department of General Surgery and Surgical Specialties, University of Modena and Reggio Emilia Medical School Surgical Clinic, Modena, Italy

JetPeel™-3, tested in 20 adult volunteers, consisting in the addition to the standard protocol of an anesthetic, carbocaine and a sterilizing and disinfectant agent, that is chlorexidine. In fact disinfection and sterilization of the skin surface is a peculiar step for every antiaging or therapeutic procedure. The procedure has been completed with multiple hyaluronic acid injections of the skin in order to achieve face rejuvenation. The anesthetic power of the JetPeel™-3-carbocaine protocol has been compared to the Emla cream one.

Results. The spontaneous pain sensation perceived by the patients in the hemiface treated with JetPeel™-3 was significantly lower compared to the hemiface treated with Emla cream ($P < 0.001$) showing, consequently, that JetPeel™-3-carbocaine protocol had the best anesthetic performance either in dermal, subdermal or subcutaneous injections compared with Emla cream.

Conclusion. JetPeel™-3 has proved to be a good non-invasive approach and its use is recommended since it induces local anesthesia in a short time.

Key words: Rejuvenation - Keratolytic agents - Pain.

Facial aging is the result of intrinsic or genetically determined and extrinsic factors including sun exposure, smoking, diet, and general lifestyle leading to loss of skin elasticity, lines, wrinkles and dyspigmentation.¹⁻⁴ Furthermore, face aging is the result of interactions, at different anatomical levels, *i.e.*, skin, subcutaneous fat, muscle and bone and it is characterized by atrophy of subcutaneous fat pads and the overlying skin droops due to loss of the underlying support which may be exacerbated by cutaneous photodamage.⁵⁻¹⁴ In particular UV irradiation is considered to be the primary environmental factor which causes skin aging.¹ The interest to reverse the signs of aging, caused by photodamage, is rising leading to the growing use of several procedures for facial skin rejuvenation to try to minimize the erythema, dyspigmentation, and rhytides associated with photoaging.⁵ Among these procedures, the percutaneous collagen induction (PCI) therapy (skin needling) can be used to treat photoaged skin without the risk of skin dyspigmentation;¹ the ablative laser resurfacing is the most precise and important technique for facial skin rejuvenation, although it is associated with significant patient downtime and risks of adverse effects such as scarring and dyspigmentation; the intense pulsed light is a non-ablative procedure that targets dermal collagen without damaging the epidermis and effectively targets both the erythema and dyspigmentation seen in photoaging minimizing side effects and patient downtime although it does not match the results seen in fully ablative procedures; the fractional laser technologies, first non-ablative and more recently ablative, represent the most recent attempt to match the results seen in fully ablative procedures with less patient downtime.⁵ The aging of the skin can be counteracted by means of cosmeceuticals, laser rejuvenation, chemical peels, and microdermabrasion.² For many years surgery has been the key resource in esthetic medicine to try to rejuvenate skin, but nowadays the non-surgical procedures are the treatment of choice due to their low invasiveness and shorter recovery time for the patient.⁷ An example is given by a non-

ablative treatment modality, called radiofrequency (RF) tissue tightening. This technique has been developed to create thermal effects in the dermis without external cutaneous wounding to respond to the growing of rhytides, wrinkles, and other signs of photoaging due to a greater sun exposure, phototoxic drugs, and demographic changes.⁷ Among the minimally invasive techniques, used to fight against the aging process, we can also find botulinum toxin (BTX), intradermal fillers and chemical peels.¹⁴ The first documented use of peeling by a physician is found in the Egypt-Ebers papyrus (1560 B.C.) where it is described its use to remove wrinkles as well as in other cosmetic treatments.⁶ Peeling techniques can be either chemical or mechanical: 1) chemical peeling consists in applying a chemical solution to the face in order to cause controlled peeling of the superficial layers of the skin; 2) dermabrasion is obtained by means of a mechanical device which is used to resurface the skin by removing the same layers (a variety of abrading techniques are available, the most popular one being a small rotating abrasive wheel applied to the skin.¹⁰ Chemical peeling and dermabrasion are useful in treating uneven areas of skin pigmentation and removing keratoses, lentigines, and acne scarring, but they can also be used to alter the epidermis and dermis of the skin to slow the aging process.⁹ Chemical peeling has been widely used to rejuvenate skin since it can improve damaged skin and fine wrinkles.⁸ Moreover, this peeling technique may be used to treat pigmentary disorders, superficial acne scars, aging skin changes, and benign epidermal growths, although some contraindications exist and they include patients with an active bacterial, viral or fungal infection, a tendency to keloid formation, facial dermatitis, taking photosensitizing medications and unrealistic expectations.¹³ This procedure has been described as a controlled chemical burn of the epidermis and/or dermis resulting in epidermal regeneration and postinflammatory collagen neoformation with remodelling of collagen and elastic fibers and deposition of glycosaminoglycans in the dermis.¹³ A classification of chemical

peels, based upon the depth of the wound created by the peel, has been reported by Landau¹¹ who describes three categories: 1) superficial peels that penetrate the epidermis only; 2) medium depth peels that damage the entire epidermis and papillary dermis; 3) deep peels that create a wound to the level of the midreticular dermis. The same author underlines that the depth of the peels determines the patient's inconvenience during and after the procedure, the healing time, the rate of the potential side effects and the results. Several peeling methods, such as a salicylic acid derivative, beta-lipohydroxy acid and alpha-hydroxy acids like glycolic acid, have been used by demarmatologists and plastic surgeons. In particular superficial peels are an important tool to enhance treatment of clinical conditions such as acne, melasma, dyschromias, photodamage and actinic keratoses.³

The present preclinical study was designed to assess the effective ability of chlorhexidine 2%, to sterilize the skin by means of swab culture and compare the spontaneous degree of pain, by means of the Visual Analog Scale (VAS) of Scott-Huskisson, recorded after the puncture of 10 volunteers' forearms with needles of several sizes to the degree of pain recorded after the injection following carbocaine administration. After the preclinical study, we carried out a clinical study involving 20 volunteers to assess the safety and the efficacy of the JetPeel™-3 system. It was used on the patient's half face in combination with carbocaine as a peeling modality to achieve skin rejuvenation, focusing in particular on its anesthetic power measured by Scott-Huskisson VAS and compared to Emla cream on the patient's other half face. Chlorhexidine 2% was used to sterilize the skin as a preliminary step before performing any procedure.

Materials and methods

Technology and device

JetPeel™-3 (Tav Tech Inc., Yehud, Israel) is a medical device for the skin surface treat-

ment with different claims such as surfacal smooth dermoabrasion, blackspots skin clearing, fine wrinkles smoothing, skin cleaning and dilated pores squeezing, dermo-epidermic hydration and oxygenation, rheologic improvement of microcirculation, dermal lymph drainage and drug dermal delivery.¹⁰

The basic principle of this instrument is very easy and revolutionary. A mixture of saline and oxygen is forced into an open converging-diverging Venturi channel, which accelerates the droplets to a speed of 200 m/s to the output through purposely designed nozzles, thus addressing a powerful water-drug-air-oxygen microdroplet jet (diameter ranging between 5 and 200 µm) onto the skin surface.

The spray power arising from a pressurized gas source (oxygen, or nitrogen or air) is supplied at 7 atmosphere pressure and mixed with fluid on a separate disposable handpiece.

The spray flow is emitted through a tubing system and a handpiece triggered by a footswitch, while a separate suction system aspirates gas and phragments. We reasonably suggest to enclose the Jet Peel™-3 as a preliminary step in our rejuvenation protocol with fillers and/or mesotherapy cocktails for two main reasons: 1) the need to have a very clean pathogen-free and germ-free skin surface before injections, clearing out the impurities due to contaminants and removing bacteria to reduce the risk of contamination and infection rate; 2) the need to perform painless injections even in a great number, avoiding anesthetic creams (like Emla and eutectic mixture ointment of prilocaine and xylocaine) that are cumbersome and must be dispensed one hour before the needle invasive procedure. Moreover, on the other hand, truncal and cutaneous anesthesia are quite invasive and the procedure modifies the skin appearance due to the needle trauma and injected fluid volume.¹⁵

Preclinical study

We performed a preliminary pilot study on 10 volunteers' (females = 8; males = 2; age between 30 and 67 [44.5±3.97,

mean \pm SE]) forearm skin comparing the results of a skin swab culture to a second skin swab culture, performed on the same skin five minutes after administration of 1 mL of chlorhexidine 2% (Johnson & Johnson, Milan, Italy), by means of JetPeelTM-3. Later on, the intensity of spontaneous pain after puncturing the subject's skin with 16-18-21-Gauge needles was compared to the intensity of spontaneous pain perceived by the same subjects receiving the same puncture with the same needles after being sprayed by means of JetPeelTM-3 with 1 mL carbocaine 1% (Astra Pharmaceuticals, Milan, Italy) for five minutes over a 1.5 x 1.5 cm spot. The data, describing the intensity of pain obtained from this pre-clinical study, were compared basing on the Scott-Huskisson Visua Analog Scale (VAS) as described by Maratea *et al.*:¹²

- slight pain=values <44 mm (RANGE 1);
- moderate pain=45 mm <values >69 mm (RANGE 2);
- strong pain=70 mm <values >88 mm (RANGE 3);
- very strong pain=values >88 mm (RANGE 4).

Clinical study

The clinical study group consisted of 20 adult volunteers (females=18; males=2), aged between 32 and 75 (50 \pm 2.68, mean \pm SE). The protocol was based on chlorhexidine 2% antiseptic solution, sprayed by means of JetPeelTM-3, with oxygen for five minutes over the face surfaces to be treated (2-6 cc accordingly to the wide area), followed by carbocaine 1% (10 cc) sprayed by means of JetPeelTM-3 over the same pre-sterilized and partially desquamated area (five minutes). Each patient's half face was pretreated with JetPeelTM-3 according to the chlorhexidine-carbocaine protocols and the other half with simple chlorhexidin embedded cotton swab followed by Emla cream (lidocaine 2.5% and prilocaine 2.5% [Astra Pharmaceuticals, Milan, Italy]). Emla cream is an emulsion in which the oil phase is an eutectic mixture of lidocaine and prilocaine in a ratio of 1:1 by weight. After that

we proceeded with the filler injections. We used Viscofill (IBSA, Lodi, Italy) and Viscoderm (IBSA). Viscofill is a polivinylsulfone crosslinked fermentative hyaluronic acid (molecular weight =10⁶ Dalton) used for prolonged filling of wrinkles and Viscoderm is a non-crosslinked native hyaluronic acid (molecular weight=10⁶ Dalton) used in mesotherapy multiple injections to stimulate fibroblast dermal chemotaxis.

The needles used to perform the filler injections were sterile 31-Gauge stainless steel supplied directly in the package of the product.

Statistical analysis

Statistical analyses were performed using Minitab[®] (v. 15.1; UK). The data for carbocaine administration and Emla cream application were checked for normality using the Anderson-Darling test. Since these data are not normally distributed, the logarithmic transformation was applied. The spontaneous pain data, measured using the Scott-Huskisson VAS, after carbocaine administration compared to Emla cream application, were analysed using a two-sample t-test. A value of P<0.001 was considered significant.

Results

Preclinical trial

The administration of 2% chlorhexidine showed a complete skin sterilization. The comparison of the skin swab culture, taken before and after the skin was sprayed for five minutes with 2% chlorhexidine, was effective in removing from the skin surface all the pathogens (Table I).

The second part of the preclinical study showed that the needle punctures (16-18-21-Gauge) were completely painless after five minute carbocaine administration by means of JetPeelTM-3. In fact the recorded VAS pain sensitivity for the injection without carbocaine fell in the third range for the 16-Gauge needle, while the pain sensitivity,

TABLE I.—Comparison of the swab culture performed before and after a 5 minute spraying of 2% chlorhexidine by means of JetPeel™-3.

Patient	Before chlorhexidine	After chlorhexidine
1	Saprophyte Staphylococcus Streptococcus	No growth observed
2	Streptococcus epidermidis Sarcinae	No growth observed
3	Staphylococcus aureus Mixed gram positive bacteria	No growth observed
4	Proteus Staphylococcus Streptococcus	No growth observed
5	Candida Mixed cocci	No growth observed
6	Saccaromyces Staphylococcus Streptococcus	No growth observed
7	Streptococcus epidermidis E. Coli	No growth observed
8	Haemophilus Mixed cocci	No growth observed
9	Sarcinae Acinetobacter Mixed cocci	No growth observed
10	Mixed gram positive bacteria	No growth observed

recorded after the carbocaine injection, fell in the first range. As for the other two needle sizes, the spontaneous pain, recorded after the injection without carbocaine fell, in the second range, while the pain, measured after the injection with carbocaine, fell in the first range. The VAS values (mean \pm SE; mm) for both groups are reported in Table II.

Clinical study

The patients' admission criteria were: aging face, wrinkles and acne scars to be treated with a dermal filler.

No anxiolytic drug or any other medication had been admitted in the last 96 hours before the session. The areas to be treated

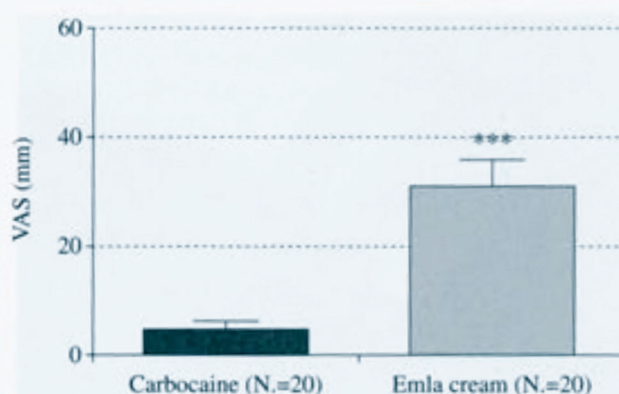


Figure 1.—Comparison between the JetPeel™-3-carbocaine protocol anesthetic power and the Emla cream one. The degree of pain was measured by means of Scott-Huskisson VAS (mean \pm SE; mm).

were nasolabial folds, glabella, upper lips and filter, chin, periorbital and cheeks. Each patient's half face was pre-treated with Jet-Peel™-3 according to the chlorhexidine-carbocaine protocols, and the other half with simple chlorhexidin embedded cotton swab followed by Emla cream ointment administration and polyurethan sheet occlusion one hour before the procedure. The treated side and the control side of the face were chosen randomly in order to avoid side dominance bias. After both hemifaces had been sterilized with chlorhexidine, we proceeded with the carbocaine jet by means of JetPeel™-3 on half of the face (Figure 1) and with Emla cream ointment on the other half. Then we started injecting the filler, Viscofill and subdermal Viscoderm on both hemifaces, giving to Emla cream 20 minutes to be absorbed. The injection techniques were straight subdermal along the wrinkle line, criss-cross and fanning for the polymerized hyaluronic acid and picotage for Viscoderm (Figures 2-4). Each patient received between 30 and 90 injections (55 ± 4.47 , mean \pm SE).

TABLE II.—Preclinical trial. Normal injection versus post-carbocaine injection (needles of three different sizes have been used). The degree of pain was measured by means of Scott Huskisson VAS (mean \pm SE; mm).

Normal injection (N=10) - 16-Gauge needle (mean \pm SE)	Injection after carbocaine jet (N=10) - 16-Gauge needle (mean \pm SE)	Normal injection (N=10) - 18-Gauge needle (mean \pm SE)	Injection after carbocaine jet (N=10) - 18-Gauge needle (mean \pm SE)	Normal injection (N=10) - 21-Gauge needle (mean \pm SE)	Injection after carbocaine jet (N=10) - 21-Gauge needle (mean \pm SE)
88 \pm 3.26	2.5 \pm 1.11	65 \pm 6.05	1 \pm 0.66	52.6 \pm 4.83	1 \pm 0.66

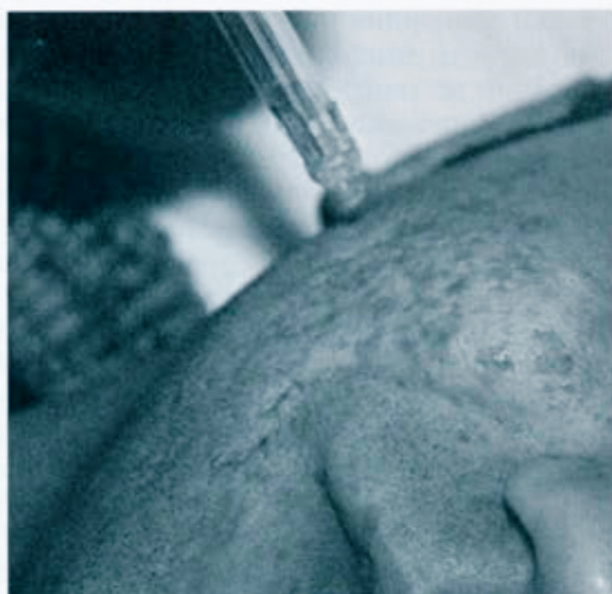

Figure 2.—Carbocaine perfusion by means of JetPeel™-3.

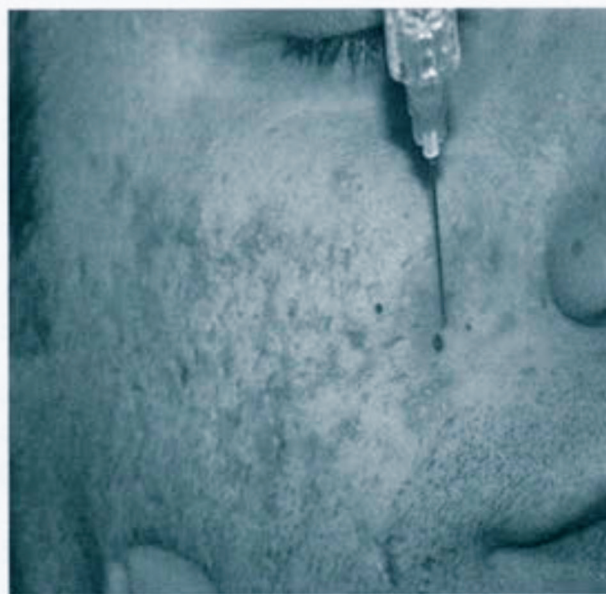

Figure 4.—Painless injection of hyaluronic acid by means of a 23-Gauge needle.

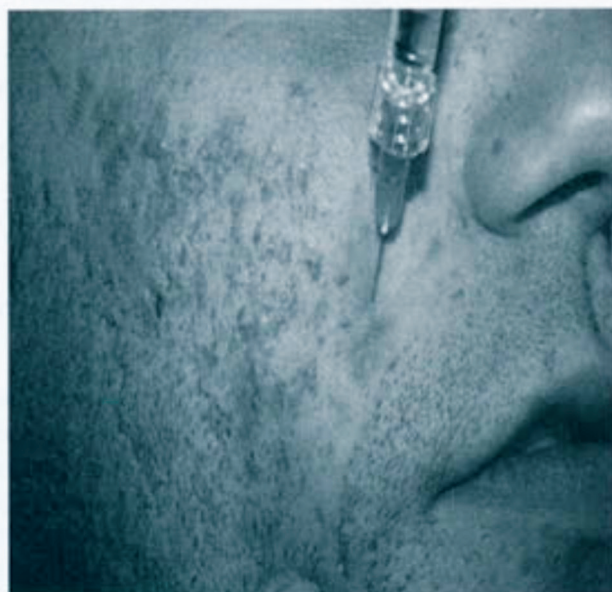

Figure 3.—Painless injection of hyaluronic acid with a 18-Gauge needle.

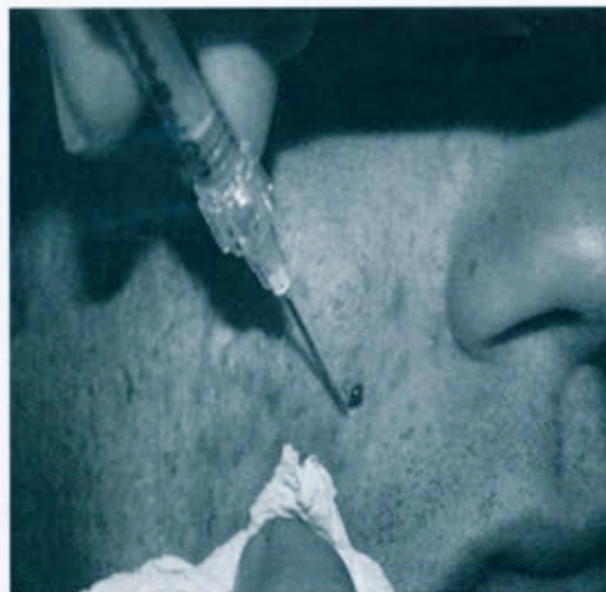


Figure 5.—Painless injection of hyaluronic acid by means of a 21-Gauge needle.

Immediately after the injection on each hemiface, the intensity of the overall tolerated pain was assessed for each individual patient by means of Scott-Huskisson VAS. All the patients completed the trial and no dropout, due to discomfort or pain, was recorded. The spontaneous pain sensation perceived by the patients in the hemiface treated with JetPeel™-3-carbocaine was significantly lower com-

pared to the hemiface treated with Emla cream ($P < 0.001$; Figure 5) showing, consequently, that JetPeel™-3 had the best anesthetic performance either in dermal, subdermal or subcutaneous injections compared with Emla cream. As a matter of fact Emla anesthesia was almost surfaceal. Especially along horizontal needle tracks, in the very sensitive areas (lipo contour, periobital wrinkles, glabella), the patients

TABLE III.—Pain sensitivity measured by Scott-Huskisson VAS (mean \pm SE; mm).

Treatment	Scott-Huskisson VAS(mm; mean \pm SD)
Carbocaine (N.=20)	4.70 \pm 1.406
Emla cream (N.=20)	30.95 \pm 4.84

showed some, even if inhibited and self-controlled, muscular reactions. The pain sensitivity data measured by Scott-Huskisson VAS (mm) are reported in Table III.

Conclusions

This study shows an approach to face rejuvenation by means of JetPeel™-3. This instrument is effective in terms of skin preparation and anesthesia when we choose multiple injections or sequential mesotherapy as a treatment. This study shows its effectiveness if either cross-linked or natural hyaluronic acid are injected contemporarily to achieve the best cosmetic effect.

JetPeel™-3 is a very easy and original tool to achieve an ideal skin-drug interaction and penetration if the molecular weight of the delivered compound is not too much heavy to be transferred across the healthy skin layers and if the electric charges (hydrophobicity *versus* hydrophilia) do not inhibit absorption.

As to the dynamic jet pressure of the gas, it helps the liquid droplets to release the squamous layers sheets of the skin with a kinetic energy that is related to the square of its mass and to the impact velocity. Thereafter the drug molecules are released and partially swept off on the surface, partially penetrate into the skin texture down to the dermal papillae and potentially to the blood stream through dermal microcirculation.

In our protocol the second step of carbocaine administration, after the first sterilizing and peeling washout, enhances the anesthetic compound uptake due to the horny layer and the epidermal thickness partial reduction achieved in the first part of the procedure.

In this study we show that JetPeel™-3 mediated anesthesia is superior to Emla cream administration. In fact its penetration is due to simple skin diffusion and not actively pushed by jet force.

In our labs ongoing studies will involve vasoconstrictor (adrenaline) synergistic penetration with JetPeel™-3 and comparisons of different local anesthetic compound effectiveness.

We believe that JetPeel™-3 induced local anesthesia is, at the moment, among the best non-invasive approach to people, especially children with fear of the needles, or in cases, like rejuvenation procedures and mesotherapy, where multiple injections are required. In this specific field our protocol is extremely safe and effective as it is also able to prevent the infection risk. In the surgical area JetPeel™-3, both skin cleaning and anesthesia are very helpful especially for the lasers, cavitation and intense pulsed light instrument procedures as it withdraws the need of cooling the skin with some possible bias due to the impact between epidermal low temperature and the vaporizing and heating beam. We believe that in treatment of teleangiectasia, angiomas and melanin spots, and specifically in the pediatric area, JetPeel™-3 can be the gold standard procedure.

Riassunto

Procedure cosmetiche di ringiovanimento facciale: focus sull'effetto preoperatorio antisettico e anestetico del JetPeel™-3 (device a rilascio di ossigeno ad alta pressione)

Obiettivo. Oggigiorno c'è un grande attenzione nel tentare di rallentare il processo di invecchiamento facciale. La medicina estetica si è basata per molti anni su un approccio di tipo chirurgico, ma adesso, per correggere il problema dell'invecchiamento, l'interesse si è spostato verso l'utilizzo di tecniche non invasive, possibilmente indolori, che possano garantire al paziente un recupero veloce dopo la procedura. In questa prospettiva è in evidente aumento l'utilizzo di peeling chimici e della dermoabrasione per migliorare il ringiovanimento cutaneo. Queste tecniche sono anche utili per trattare le irregolarità della pigmentazione cutanea e

rimuovere cheratosi, lentiggini, acne e altre condizioni cutanee. Uno dei più interessanti sistemi, sicuro e indolore, utile per il trattamento del viso, è JetPeel™ -3. Scopo dello studio era verificare l'efficacia di questo strumento.

Metodi. Il meccanismo d'azione di questo dispositivo medico è basato sul rilascio di un costante flusso d'aria ad alta pressione, incluso ossigeno, insieme ad altri differenti composti chimici come molecole per peeling, antiossidanti, vitamine e acido ialuronico, che sono forzate meccanicamente attraverso la superficie cutanea. In questo studio riportiamo un nuovo approccio all'uso clinico di JetPeel™ -3, testato in 20 volontari adulti, consistente nell'aggiunta al protocollo standard di un anestetico, la carbocaina, e di un agente disinfettante e sterilizzante, la clorexidina. Infatti la disinfezione e la sterilizzazione della superficie cutanea sono uno step peculiare per ogni procedura antiaging e terapeutica. La procedura è stata completata con iniezioni multiple di acido ialuronico, per migliorare l'aspetto della cute. Il potere anestetico della carbocaina, veicolata con JetPeel™ -3 è stato paragonato con quello della crema Emla ($P < 0.001$).

Risultati. La sensazione di dolore, percepita dai pazienti nella parte del viso trattata con il protocollo JetPeel™ -3-carbocaina, era significativamente più bassa rispetto a quella percepita nella parte del viso trattata con la crema Emla ($P < 0,001$). Ciò dimostra che tra i due, JetPeel™ -3 ottiene i risultati anestetici migliori sia nelle iniezioni subcutanee che in quelle subdermali e dermali.

Conclusioni. Questo studio dimostra che JetPeel™ -3 rappresenta un ottimo approccio non-invasivo e il suo uso è raccomandato per indurre anestesia locale in breve tempo.

Parole chiave: Ringiovanimento cutaneo - Agenti cheratolitici - Dolore.

References

1. Bowler PJ. Impact on facial rejuvenation with dermatological preparations. *Clin Interv Aging* 2009;4:81-9.
2. Ogden S, Griffiths TW. A review of minimally invasive cosmetic procedures. *Br J Dermatol* 2008;159:1036-50.
3. Aust MC, Reimers K, Gohritz A, Jahn S, Stahl F, Reppenning C *et al*. Percutaneous collagen induction. Scarless skin rejuvenation: fact or fiction? *Clin Exp Dermatol* 2010;35:437-9.
4. Doherty SD, Doherty CB, Markus JS, Markus RF. A paradigm for facial skin rejuvenation. *Facial Plast Surg* 2009;25:245-51.
5. Bermann PE. Aging skin: causes, treatments, and prevention. *Nurs Clin North Am* 2007;42:485-500.
6. Elsaie ML, Choudhary S, Leiva A, Nouri K. Nonablative radiofrequency for skin rejuvenation. *Dermatol Surg* 2010;36:577-89.
7. Ebbell B, translator. *The Papyrus Ebers: The Greatest Egyptian Medical Document*. Copenhagen: Levin & Munksgaard; 1937.
8. Golan J, Hai N. JetPeel: a new technology for facial rejuvenation. *Ann Plast Surg* 2005;54:369-74.
9. Giese SY, McKinney P, Roth SI, Zukowski M. The effect of chemosurgical peels and dermabrasion on dermal elastic tissue. *Plast Reconstr Surg* 1997;100:489-98; discussion 499-500.
10. Fabbrocini G, De Padova MP, Tosti A. Chemical peels: what's new and what isn't new but still works well. *Facial Plast Surg* 2009;25:329-36.
11. Mysore V, Savant S, Khunger N, Patwardhan N, Prasad D, Buddhadev R *et al*. Standard guidelines of care for chemical peels. *Indian J Dermatol Venereol Leprol* 2008;74(Suppl):S5-12.
12. Landau M. Chemical peels. *Clin Dermatol* 2008;26:200-8.
13. Berson DS, Cohen JL, Rendon MI, Roberts WE, Starker I, Wang B. Clinical role and application of superficial chemical peels in today's practice. *J Drugs Dermatol* 2009;8:803-11.
14. Onesti MG, Curinga G, Toscani M, Scuderi N. Jet-Peel: nuova metodica per gli inestetismi cutanei. *Derm Clin Vol* 2006;26:19-22.
15. Maratea N. Continual epidural therapy in lumbosacral syndrome. Personal experience. *Minerva Anestesiol* 2002;68:55-63.